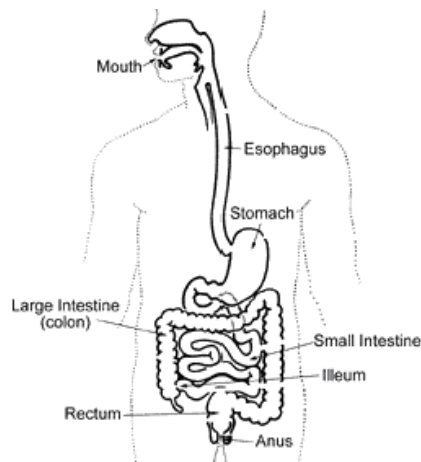


Small Bowel Bleeding and Capsule Endoscopy

Overview

What is the Small Bowel?

The small bowel (or small intestine) is the longest portion of the gastrointestinal (GI) tract. It is called "small" because it is thin or narrow compared to the "large" bowel (also known as the colon), but it is much longer than the large bowel (14 feet on average). The small intestine is a vital organ involved in nutrient absorption.



(<http://s3-patients.gi.org/files/2011/09/smallbowel.gif>)

What is Small Bowel Bleeding?

GI bleeding, including from the small bowel, occurs when an abnormality on the inner lining begins to bleed. The bleeding may be slow, resulting in anemia (a low blood count), or it may be rapid, causing a hemorrhage. Approximately 5% of all GI bleeding comes from the small bowel. In many cases, the abnormalities causing the bleeding lie within reach of a standard endoscope (see below). However, because of the length of the small bowel and its location between the stomach and colon, finding the source of bleeding can be difficult.

Bleeding from the small bowel is a rare, often difficult to diagnose cause of GI blood loss. AVMs account for 30 to 40% of cases, and are the primary source of bleeding in patients over the age of 50. Tumors (benign and malignant), polyps, Crohn's disease, and ulcers are some of the other sources of bleeding. Multiple techniques are used to diagnose and treat the source of small bowel bleeding, including: endoscopy, enteroscopy, x-ray studies, capsule endoscopy, deep small bowel enteroscopy, and intraoperative enteroscopy. AVMs can typically be treated with cautery delivered through an endoscope or enteroscope. Tumors (benign and malignant) can be biopsied and have their location marked using endoscopy, but surgery is typically required for their removal. Other conditions, such as Crohn's disease, are often treated with medications.

Causes

What causes bleeding from the small bowel?

The causes of bleeding in the small bowel are different from those in the colon or the stomach. The most frequent causes of bleeding from the colon are polyps, diverticulosis (small out-pouchings in the wall of the colon), or cancer. Upper GI (esophagus, stomach, or duodenum) bleeding is most frequently due to ulcers. Unlike the colon and the upper GI tract, however, 30 to 40% of small bowel blood loss is caused by abnormal blood vessels that lie within the wall of the small bowel. These abnormal blood vessels are called angioectasias or arteriovenous malformations (AVMs). AVMs become more common as people age and are associated with other medical problems, such as chronic kidney disease and valvular heart disease. In people over the age of 50, AVMs are the most common cause of small bowel bleeding. Other causes of small bowel bleeding include benign (non-cancerous) and malignant (cancerous) tumors, polyps, Crohn's disease (a type of inflammatory bowel disease), and ulcers. Like ulcers in the stomach, ulcers in the small bowel are often the result of the use of nonsteroidal anti-inflammatory drugs (NSAIDs).

Screening/Diagnosis

How is the small bowel examined?

There are multiple techniques for evaluating the small bowel. In most cases, the first step is endoscopy and/or enteroscopy. If that fails to find the source of bleeding, a common next step is capsule endoscopy. X-ray options include a small bowel follow-through, or a computed tomographic scan (also known as a CT or CAT scan) of the small bowel. Deep small bowel enteroscopy can now be performed using special scopes with inflatable balloons and/or overtubes. The final option, which is usually used only if other methods have failed, is intraoperative enteroscopy. All of these methods will be discussed in detail below.

What are standard endoscopy and enteroscopy?

Endoscopes and enteroscopes are instruments used by doctors to evaluate the stomach and small bowel. Endoscopy refers to the examination of the bowel using a scope. At times the term is used specifically to indicate a procedure using a standard upper endoscope, but it can also be used more broadly to include examinations done with any type of scope. Endoscopes and enteroscopes resemble long, thin tubes with a light and a camera at one end. The images obtained are displayed on a monitor. The scopes also have channels which allow instruments to be passed down them. These instruments can be used to treat lesions, to obtain biopsies, or to mark the location of a lesion with a tattoo to aid a surgeon in locating it.

The examination begins with the patient receiving a sedative. The doctor then passes the scope through the mouth. A regular endoscope is capable of examining the esophagus, stomach and the first portion of the small bowel, known as the duodenum. In cases where the source of bleeding is thought to be lower down in the small bowel, a longer scope, known as an enteroscope, can be used. This scope is capable of reaching the middle portion of the small bowel, known as the jejunum.

What types of x-ray studies are used to find the source of small bowel bleeding?

X-ray studies continue to have a role in the evaluation of small bowel bleeding, as 20-25% of bleeding episodes that originate in the small bowel are caused by abnormalities in the intestinal wall, such as tumors, that can be seen by standard or specialized x-ray studies. There are three x-ray tests commonly used in the evaluation of the small bowel – small bowel follow-through, enteroclysis, and CT enterography.

The small bowel follow-through test is a series of abdominal x-rays that are taken at different times after a patient drinks a white, chalky fluid called barium, that shows up clearly on x-rays. The test allows the doctor to examine the lining of the intestine for any irregularities. The test is good for large abnormalities, but can miss many smaller ones. However, it is safe and easy to tolerate.

A second x-ray test, the enteroclysis study, is similar to the small bowel follow-through in that it uses barium to visualize the inner wall of the small bowel. It is more invasive because it requires a small tube called a catheter to be slowly advanced from the nose down the esophagus, through the stomach and into the small bowel, to allow for air and barium to be instilled. The advantage of this study is that pictures from enteroclysis have better resolution, so abnormalities missed by the small bowel follow-through test may be detected. A disadvantage of the enteroclysis study is that it can be an uncomfortable examination due to the presence of the catheter and the use of air to distend the small bowel while taking pictures. In some cases a CT scan is used instead of regular x-rays. This allows for even more detail to be seen.

A third test is known as a CT enterography. A CT enterography is performed the same way a normal CT scan is done. The patient drinks an oral contrast solution (often dilute barium) while also receiving intravenous (IV) contrast. Then numerous, very detailed images are obtained. A CT enterography differs from a standard CT scan in that the type of contrast that the patient drinks is designed to allow for a more detailed inspection of the lining of the small bowel.

While none of these tests is perfect at finding abnormalities, the advantage of these tests is that they can sometimes find bleeding sources that are out of reach of a standard enteroscope. The major limitations of these studies are that they cannot detect AVMs, and if an abnormality is seen, there is no way to apply immediate treatment to stop the bleeding, to take biopsies to confirm a diagnosis, or to mark the location of the lesion with a tattoo. In addition, some patients are allergic to the IV contrast that is used as part of the CT scan.

What is capsule endoscopy?

In 2000, a group of doctors from England reported the use of a new instrument for determining the causes of small bowel bleeding. The device, the capsule endoscope, is 1-1/8 inches long and 3/8 inches wide (26 mm x 11 mm), the size of a large pill. It is composed of a battery with an 8-hour lifespan, a strong light source, a camera, and a small transmitter. Once swallowed, the capsule begins transmitting images of the inside of the esophagus, stomach and small bowel to a receiver worn by the patient. The capsule takes two pictures per second, for a total of approximately 55,000 images. After 8 hours, the patient returns the receiver to the doctor who downloads the information to a computer and then can review in detail the 8 hours of pictures of the capsule passing through the intestine, looking for abnormalities that are possible sources of bleeding. The patient passes the capsule through the colon and it is eliminated in the stool and discarded. The capsule is generally safe and easy to take, however, the capsule can get stuck in the small intestine if there has been prior abdominal surgery causing scarring or other conditions that cause narrowing of the small intestine. If the capsule becomes stuck, endoscopic or surgical removal is necessary. In about 15% of exams, the capsule does not view the entire small bowel prior to the battery running out and may need to be repeated.

Like x-rays, the capsule is purely diagnostic and cannot be used to take biopsies, apply therapy, or mark abnormalities for surgery. Moreover, the capsule cannot be controlled once it has been ingested, so that once it has passed a suspicious abnormality, its progress cannot be slowed to better visualize the area. Despite these limitations, capsule endoscopy is frequently the test of choice for finding a source of small bowel bleeding if standard endoscopy has failed to do so.

How effective is capsule endoscopy at detecting the source of small bowel bleeding?

In an initial study, investigators showed that the capsule was better than routine endoscopy or enteroscopy at locating small beads that had been implanted into an animal's intestine. Other studies have shown the capsule is more effective than small bowel x-rays at finding the cause of bleeding. In 2001, the first human studies reported that capsule endoscopy not only found all of the bleeding sources seen using standard endoscopy, but also an additional bleeding cause in 56% of patients for whom traditional endoscopy had not been successful. Overall, in cases of what is known as occult bleeding (blood is microscopically present in the stool, but the stool looks normal), capsule endoscopy finds a potential source of bleeding in up to 67% of patients. In cases of overt bleeding (blood is seen in the stool or the stool is black and tarry as a result of digested blood), the results are highly variable. If the bleed happened in the past, the yield may be as low as 6%. If, however, the doctor believes that there is active bleeding occurring at the time of the test, the

yield is >90%.

What is deep small bowel enteroscopy?

In cases where a lesion has been found deep in the small bowel, beyond the reach of standard endoscopy, evaluation of the deep small bowel may be required. One option to further evaluate or to treat the lesion is known as double-balloon enteroscopy. In 2004, the Food and Drug Administration (FDA) approved a new type of endoscope known as a double-balloon enteroscope (the name derives from the fact that the scope uses two balloons to aid with the examination). This scope is capable of reaching very far into the small bowel (in some cases as far as the ileum, which is the final segment of the small bowel). This scope can also be inserted through the anus, which allows for examination of the deepest parts of the small bowel (the scope must first pass through the colon). In some cases, by performing the examination through the mouth and through the anus, it is possible to examine the entire length of the small bowel, though this is not always possible. Because an examination using a double-balloon enteroscope is much more involved than standard endoscopy (it often takes hours to perform as opposed to 20 minutes for standard endoscopy), it is usually reserved for cases in which a source of small bowel bleeding out of reach of a standard enteroscope had been found on either an x-ray or capsule endoscopy. In one study, double-balloon enteroscopy was able to locate a bleeding source in 74% of patients. When a source is found, other studies have reported successful treatment in 63 to 71% (in these studies, treatment was considered successful if the patient did not require further blood transfusions).

In addition to double-balloon enteroscopy, two other options for evaluating the small bowel have been introduced. One is single-balloon enteroscopy, which is a procedure similar to double-balloon enteroscopy, though in this case there is only one balloon attached to the scope to aid with the examination. A second option is deep small bowel enteroscopy using a special spiral tube that fits over the scope and allows the endoscope to be advanced into the deep small bowel. This device works differently than balloon assisted enteroscopy and may offer the advantage of being a shorter procedure. Currently, it is only used for lesions that are likely to be reachable by inserting the scope through the mouth.

What is intraoperative enteroscopy?

In some cases, surgical assistance may be needed. Intraoperative enteroscopy is carried out in the operating room under general anesthesia. The surgeon, often working with a gastroenterologist (a doctor who specializes in the GI tract), inserts the endoscope through the patient's mouth or through a small incision in the small bowel (an enterotomy). The surgeon then advances the endoscope through the intestine, allowing for full examination of the entire small bowel. The advantage of intraoperative enteroscopy is that it allows the doctor to treat the cause of bleeding at the time of discovery (for AVMs), or to remove masses or polyps that are found. Because it is an invasive, surgical procedure, however, intraoperative enteroscopy is usually reserved for cases where other methods have failed to find or treat the source of bleeding. Overall, it is effective in treating the source of bleeding in approximately 70% of the patients who require the procedure.

Treatment

How is small bowel bleeding treated?

In cases of AVMs, a small amount of electric current can be delivered through the endoscope to cauterize the abnormality. If the AVM is discovered during endoscopy, the treatment can be applied immediately without requiring further endoscopy. If the bleeding source is found by capsule endoscopy, treatment options include endoscopy, standard enteroscopy, double-balloon enteroscopy or intraoperative enteroscopy (depending on the location of the lesion and prior attempts at treating it; see above). In rare cases where numerous AVMs are present within a segment of small bowel, the segment of small bowel may need to be removed surgically. Polyps can be removed with an endoscope or at the time of surgery in cases where the polyp cannot be removed with an endoscope. Tumors, both benign and malignant, typically require surgical removal (while benign tumors do not necessarily need to be removed in all cases, if they are causing significant blood loss removal is usually recommended). Other causes of small bowel bleeding can be treated medically (e.g., Crohn's disease or medication induced ulcers).

Authors

Anne C. Travis, MD, MSc and John R. Saltzman, MD, FACP, Brigham and Women's Hospital, Harvard Medical School, Boston, MA

Patient Links

- American Society for Gastrointestinal Endoscopy (<http://www.asge.org/PatientInfoIndex.aspx?id=390>)
- Medline Plus (Enteroscopy) (<http://www.nlm.nih.gov/medlineplus/ency/article/003889.htm>)
- Mayo Clinic (Capsule Endoscopy) (<http://www.mayoclinic.com/health/capsule-endoscopy/MY00139>)